

Press release

New research findings: competitive alpine skiing often leads to bony lesions in the knees of young skiers

Zurich, 18 June 2020 – MRI scans of young skiers often show “pseudo-lesions” in the knee joint. A study in youth competitive alpine skiers has shown that these distal femoral cortical irregularities (DFCIs) are present in more than half of the youth skiers and are of mechanical origin. Thanks to these study results, the assessment of unclear MRI findings can be improved and misdiagnoses and follow-up investigations can be reduced.

The study is a joint research project of the Radiology and Sports Medicine departments of Balgrist University Hospital in Zurich, Switzerland. The researchers examined the knee joints of youth competitive alpine skiers for the presence of distal femoral cortical irregularities (DFCIs). These are typically found at the attachment site of tendons on the posterior aspect of the femoral bone. These changes were present in more than half of the athletes while significantly fewer subjects in the control group were affected. It is thus clear that these DFCIs are of mechanical origin.

A DFCI is usually an incidental finding on an MRI scan of the knee and often does not cause any symptoms. However, in the past such findings were often misinterpreted as tumors. The results of the study, which was published in the renowned journal *Radiology*, will considerably facilitate the diagnostic evaluation of such “pseudo-lesions”. In future, follow-up investigations and invasive bone biopsies will no longer be necessary. The successful research project is an example of the interdisciplinary research activities at Balgrist University Hospital, where researchers identify clinical problems in patients and translate them into corresponding scientific questions.

Distal femoral cortical irregularity on Knee MRI: Increased prevalence in youth competitive alpine skiers. Stern C, Galley J, Fröhlich S, Peterhans L, Spörri J, Sutter R. *Radiology*, 2020. [Epub before print] doi:10.1148/radiol.2020192589

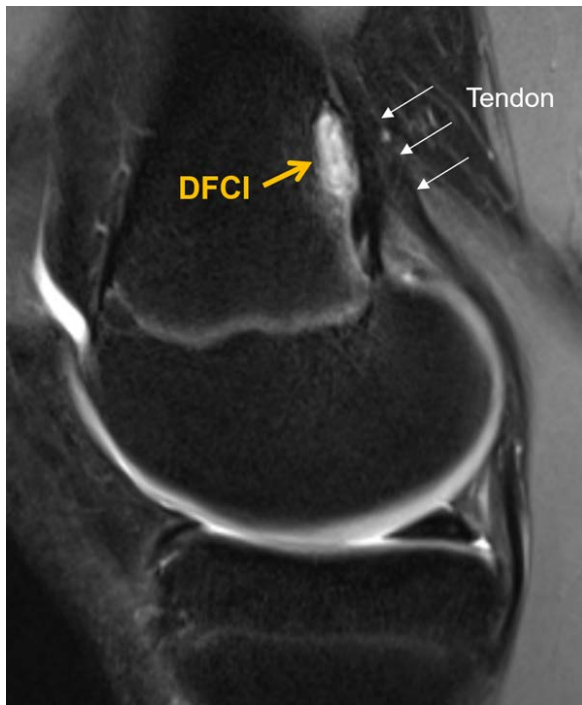
Link to the study: <https://doi.org/10.1148/radiol.2020192589>

For further information, contact

PD Dr. med. Reto Sutter, Balgrist University Hospital

Via Franziska Ingold, Head of Communications, Balgrist University Hospital
+41 44 386 14 15 / kommunikation@balgrist.ch

Picture and description



The lateral MRI image of the knee joint shows a bony alteration above the joint space, a finding called a distal femoral cortical irregularity (DFCI). This alteration is located at the typical site at the attachment of a tendon. Researchers at Balgrist University Hospital were able to show that these bony lesions are present in more than 50 percent of young skiers and are of mechanical origin. They are found significantly less often in non-athletes.

About Balgrist University Hospital

Balgrist University Hospital is a highly specialized center of excellence for the diagnostic work-up, treatment, and follow-up care of damage to the musculoskeletal system. Interdisciplinary services combine the fields of orthopedics, paraplegiology, rheumatology and physical medicine, sports medicine, neuro-urology, chiropractic, radiology, and anesthesiology.

The broad spectrum of interlinked medical treatment is complemented by nursing care, social and psychological counselling, legal advice, and integrated measures for rehabilitation and return to work. All these activities aim to provide our patients with the best possible support.

Balgrist University Hospital and the Balgrist Campus set internationally recognized standards in orthopedic research and education.

The privately owned Balgrist University Hospital is operated by the Balgrist Association.

Balgrist University Hospital
Forchstrasse 340
8008 Zurich, Switzerland
Tel +41 44 386 11 11
www.balgrist.ch